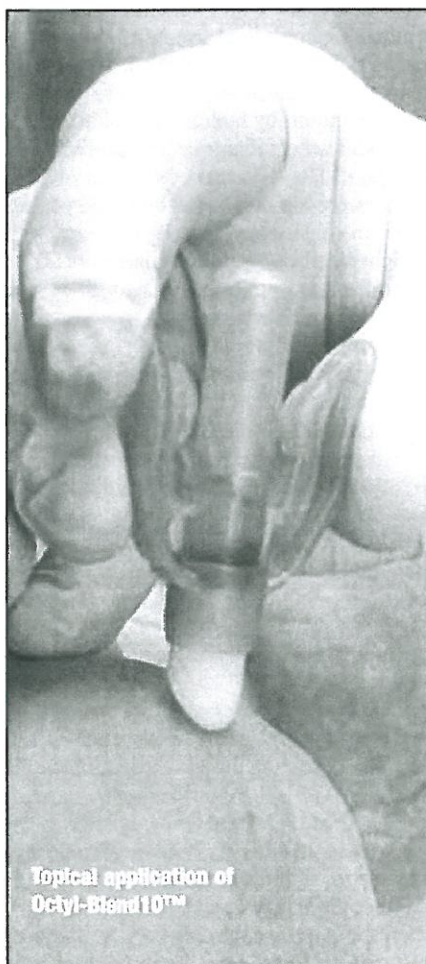

The treatment of dry heel fissures using cyanoacrylate tissue adhesive (glue): a review of 18 cases

Belinda Longhurst, private practitioner, Winchester, Hants, Elisabeth Allan, private practitioner, Hants & Ivan Bristow, lecturer, University of Southampton

CORRESPONDING AUTHOR

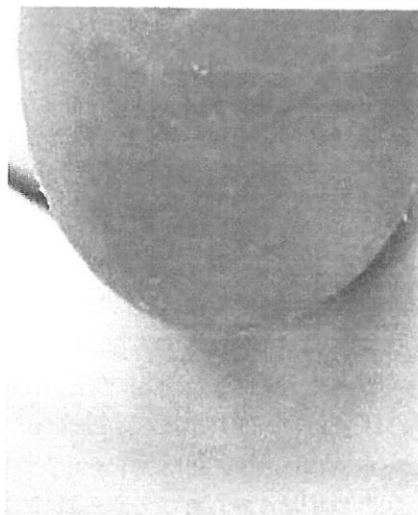
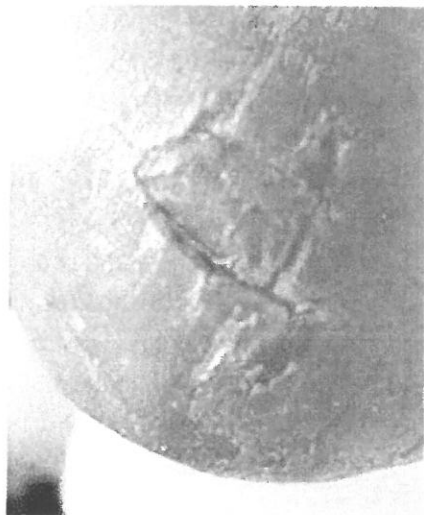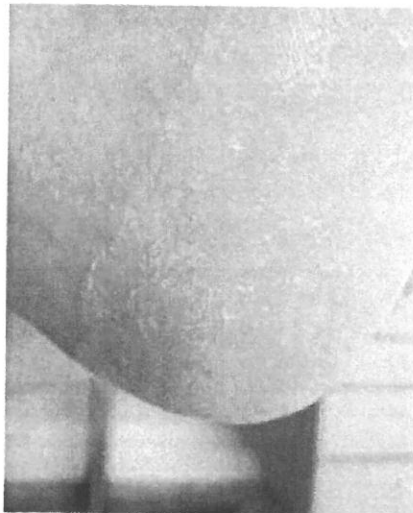
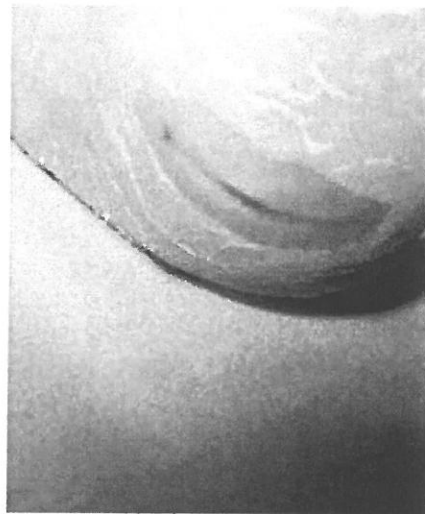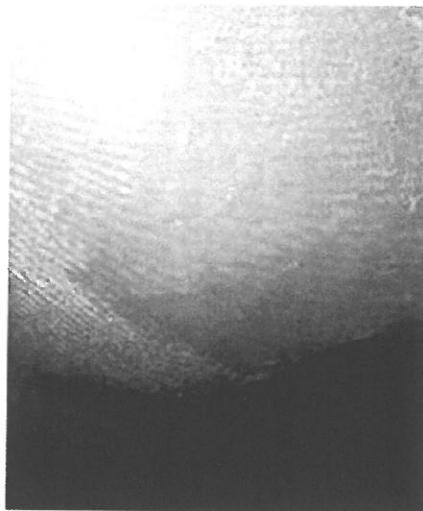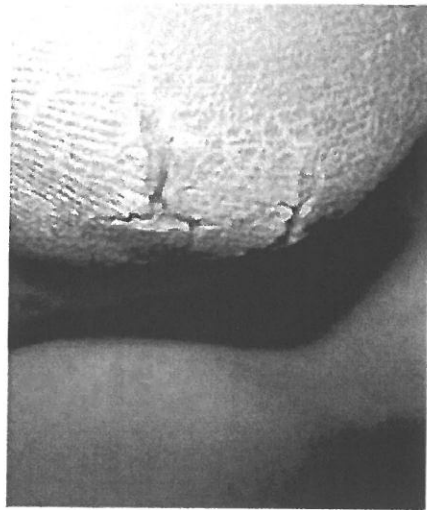Belinda Longhurst: belinda@winchesterpodiatry.co.uk



Topical application of Octyl-Blend 10™

Topical tissue adhesives have been used widely in healthcare for the closure of wounds and lacerations.¹ A recent Cochrane review² has indicated the benefit of this modality over other more traditional types of closure. However, little investigation has been undertaken into the potential applications of tissue adhesives in podiatry, such as closure of dry heel fissures, which often cause pain and offer a challenge for podiatrists to manage effectively.³

Here we present a case series reporting the use of glue in the management of dry heel fissures. A review of 18 patients treated with Octyl-Blend¹⁰™ tissue adhesive (MedLogic Global Ltd®, Plymouth, UK) was undertaken across four private practices in Hampshire. Each patient underwent administration of tissue adhesive by the podiatrist and was followed up for a minimum of three weeks. Outcomes were measured using a patient/practitioner evaluation and feedback form and digital photographs of the lesions before, during, immediately after and three weeks post-treatment. Overall the response was positive from patients and practitioners alike with regard to ease of application, aesthetics and patient comfort. During the study period, 94% (17 patients) of lesions healed with no adverse events. Instant and lasting pain relief following application was reported by the majority of patients. Dehiscence of the fissure occurred in only one subject. This exploratory work suggests that cyanoacrylates, and the Octyl-Blend¹⁰™ tissue adhesive in particular, may have a place in the management of painful heel fissures.



Before and during treatment.

After treatment.

Application of Octyl-Blend¹⁰™ to patients' heels.

Fissures are splits in the epidermis that can extend to and involve the dermis. These are usually found at sites where the skin is under tensile stress, for example around the heel margin, being associated with hyperkeratosis and anhidrosis.⁴ The main symptoms for patients are pain, itching, bleeding and embarrassment. Discomfort can make walking and weight bearing difficult, whilst the embarrassment of thick, callused heel fissures can psychologically affect a person.⁵

Moreover, such lesions can act as a portal of entry for secondary infection. Systemic and peripheral states that affect skin quality can render some people more prone to the condition than others, such as patients with diabetes, peripheral vascular disease, rheumatoid arthritis, pregnancy, obesity, systemic sclerosis, dermatitis, ichthyosis, palmoplantar keratoderma, psoriasis and tinea pedis.⁶

Historically, management of dry fissures has required removal of the source if possible. For instance, in-shoe devices can be used to alter forces on the tissue under stress, or the removal of allergens or treatment of tinea pedis, etc, can reduce or eliminate the underlying cause.⁷ Debridement of hyperkeratotic tissue and optimising epidermal strength is also paramount to assist resolution. This can be achieved in controlling stratum corneum water content, by hydrating anhidrotic skin with an emollient or hydrocolloid dressing.⁸ However, anecdotally, dry heel fissures are difficult to heal because of the mechanical stresses brought about by weight bearing. Standard treatments for hyperkeratosis are of little use once a painful fissure develops.⁹ Thus, the requirement to promote healing and, more importantly, instant and lasting pain relief by means of closing the fissure should be explored.

Cyanoacrylate topical skin adhesives

Fissures, or cuts in the skin, often need to be closed to ensure rapid and uncomplicated healing. Traditionally, there have been four ways to join tissue together: sutures, staples, tapes and synthetic tissue adhesives. Sutures, staples and tapes work well in non-weight bearing post-operative situations,¹⁰ but are also associated with a number of surgical complications, including discomfort, infection and inflammation.¹¹

Hashimoto⁹ asserts that treatment of lacerations in emergency room situations has shown that cyanoacrylate tissue adhesive is less painful to use and faster than suturing or tape. He also recommended the use of 'off-the-shelf

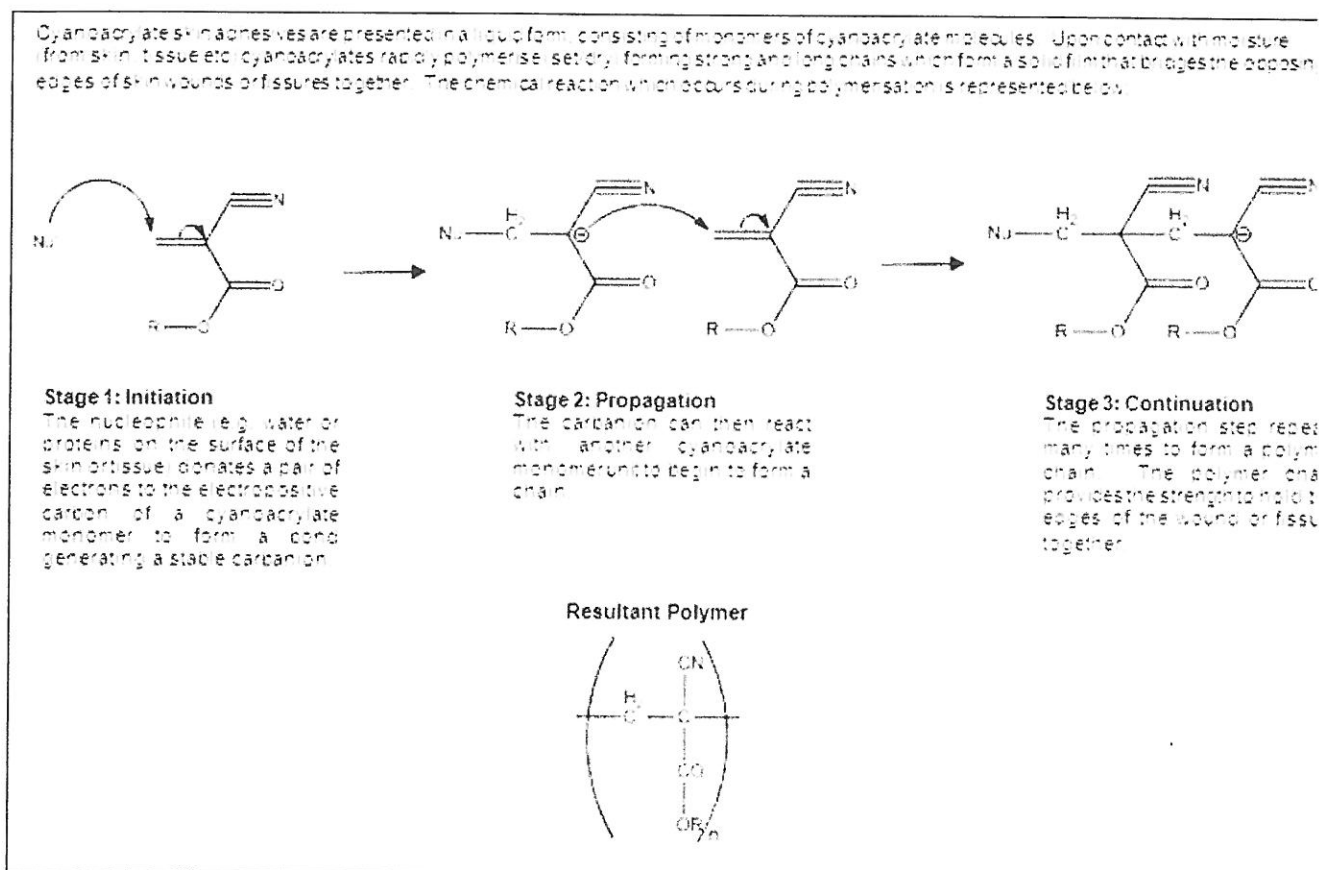


Figure 1. Reaction mechanism of cyanoacrylate anionic polymerisation.

Superglue[®] for the treatment of heel fissures in patients with diabetes. Octyl-Blend¹⁰™ tissue adhesive (MedLogic Global Ltd[®], Plymouth, UK) is a CE marked product that is licensed for the closure of skin cuts and abrasions. The product was adopted across four private practices in Hampshire and after an initial period was evaluated for its effectiveness in the management of dry heel fissures.

Singer *et al*¹² reviewed the structure and function of cyanoacrylate topical tissue adhesives as well as their advantages, indications and clinical application for optimal use. They detailed how the basic cyanoacrylate has been distilled to achieve purity and remove any toxic by-products, resulting in a low viscosity liquid (Figure 1). On contact with various anionic substances, such as blood, the cyanoacrylates polymerise into long chains, forming a solid film that bridges the wounds and holds the apposed wound edges together. Because the adhesive film generally sloughs off within 5 to 10 days as the epidermis regenerates, there is no need to remove the adhesive.

Of particular importance, Singer *et al*¹² also highlighted that topical tissue adhesives should be used in conjunction

with immobilisation in areas of high tension, due to the increased risk of dehiscence. Therefore, it is advisable to take measures to mitigate the tensile stress associated with heel fissures¹³ in addition to encouraging hydration of the tissues by regular moisturising and application of tissue adhesives to the fissure. Saxena & Willital¹⁴ suggest that wounds in areas of high skin tension (hands, feet and over joints) can be successfully treated with tissue adhesive if excessive movement is restricted. This may be achieved through use of heel cups and orthoses, and advice should be provided on supportive and accommodative footwear.

A recent Cochrane review² to determine the relative effects of various tissue adhesives and conventional skin-closure techniques on the healing of surgical wounds indicated that tissue adhesives are an acceptable alternative to standard wound closure for repairing simple traumatic lacerations. Eight randomised controlled trials (630 patients) were reviewed where tissue adhesive, stitches and/or adhesive tape were used for wound closure. No statistically significant differences were found between various tissue adhesives and sutures for

dehiscence, infection or satisfaction with cosmetic appearance when assessed by general satisfaction of patients or surgeons.

Nor were differences found between tissue adhesive and tapes (two trials) infection, patient assessment of cosmetic appearance, or patient or surgeon satisfaction. However, where tissue adhesive was utilised, they noted the benefits of decreased procedure time, including no requirement for a follow visit for removal of stitches, and less pain was observed in comparison (verified pain scores) with standard wound closure.

When considering a wound closure device, ideally it should be easy to use rapidly acting, and painless, resulting in pleasing cosmesis, no requirement for device removal and, importantly, be cost effective. Topical cyanoacrylate tissue adhesives offer many of the characteristics of this ideal wound closure device. Studies have clearly demonstrated that a moist environment is best for optimal wound healing.¹⁵ Octylcyanoacrylates are reported to create an occlusive wound healing environment and a barrier to microbial penetration.¹⁶




Figure 2. Pain scale before and after application of tissue adhesive.

Methods

Across four private podiatry practices in Hampshire, a review of cases was undertaken to identify patients receiving treatment of dry heel fissures using the Octyl-Blend¹⁰™ tissue adhesive. Eighteen patients presenting in four private practices in Hampshire, with dry fissuring of the heels treated with the modality, were identified. Data from the four locations were pooled for analysis.

Across the four practices, a standard treatment approach was adopted prior to the evaluation. Before treatment with the adhesive, fissures were measured and photographed. Questionnaires were utilised by the podiatrists to ascertain any underlying systemic pathology that could complicate healing and any previous treatment methods, or products used by the patient. Overall practitioner and patient satisfaction scores were measured according to aesthetics and comfort, in addition to patient pain scales, all of which were documented on the questionnaire on a scale of 1 to 10. Pain scores were recorded prior to treatment using a 100mm visual analogue scale, immediately after adhesive application and three weeks after the initial application of the adhesive.

Each patient underwent administration of Octyl-Blend¹⁰™ tissue adhesive following callus reduction by the podiatrist. Wound edges were opposed manually and the Octyl-Blend¹⁰™ tissue adhesive was applied in two thin continuous layers,

allowing 30 seconds to polymerise between layers. It was noted by the authors that due to the low viscosity of the tissue adhesive, care had to be taken to ensure that excessive runoff did not occur, or that the tissue adhesive was allowed to wick or seep into incompletely opposed edges during application. This was easily avoided by horizontal positioning of the wound surface and careful, controlled expression of the adhesive from the tip of the applicator. Patients were followed up at three weeks to assess results.

Results

Fissure size ranged from 0.5mm to 3mm in depth (mean = 1.55mm) and 3mm to 20mm in length (mean = 10.55). Improvement in terms of instant and lasting closure of the fissure was achieved in 94% (17) participants along with remarkable immediate and long-term pain relief following application (see Figure 2). It was noted that the instant pain relief could be attributed to sharp reduction of the callus alone, although anecdotal responses (not recorded in questionnaire) from patients reported improved immediate pain relief in comparison to previous treatment methods.

Dehiscence of the fissure occurred in only one patient. In this case, the practitioner noted that the edges were not easily approximated and the fissure was a high-tension wound. Underlying systemic conditions that could potentially

complicate healing were noted to be present in 50% (9) of patients; however this was not observed as a poor outcome marker by practitioners.

Patient satisfaction was recorded as 78% (14) of participants commenting positively on the convenience of being able to lightly shower the treated area. These also expressed appreciation for not having to wear an unsightly dressing. Practitioner satisfaction was calculated according to ease of use of applicator and strength or quality of closure obtained. In total, 88.9% (16) cases were reported by podiatrists as having pleasing results.

Limitations

The authors acknowledge that this represents a relatively small case series, within a restricted geographical area and timetable. A larger scale investigation, with objective measures using a control intervention, over a longer period of time would provide a more detailed picture of its use and effectiveness. However, this has demonstrated that skin adhesives have the potential to be of benefit in the management of painful, dry heel fissures in the potential applications in podiatry.

Conclusion

The introduction of tissue adhesives was received enthusiastically by both patient and practitioner, in this case series. This preliminary investigation indicates that cyanoacrylates, and the Octyl-Blend¹⁰™

tissue adhesive in particular, may have a place in the successful management of heel fissures. Of greatest significance was the immediate and long-term pain relief reported by the majority of patients with painful dry heel fissures. The tissue adhesives functioned as an occlusive dressing with a reported microbial barrier, and were aesthetically pleasing to patients.

Whilst they are simple to use and present many potential advantages, they are not suitable for all wounds, i.e. areas of high tension, as with major biomechanical anomalies, or where infection is present. A greater understanding of the mechanical properties, advantages and disadvantages of these cyanoacrylates will aid the podiatrist to establish their indication and use.

Declaration

All adhesive samples for this study were supplied by Medlogix (UK) Ltd. Distributed in the UK by Bailey Instruments Ltd.

References

1. Beam JW. Tissue adhesives for simple traumatic lacerations. *Journal of Athletic Training* 2008; **43**(2): 222-224.
2. Coulthard P, Esposito M, Worthington HV, van der Elst M, van Wes OJF, Darcey J. Tissue adhesives for closure of surgical incisions. *Cochrane Database of Systematic Reviews* 2009; **3**. Art No: CD004287. DOI:10.1002/14651858.CD004287.pub2.
3. Singh D, Bentley G & Trevino SG. Callosities, corns and calluses. *British Medical Journal* 1996; **312**(6) (7043): 1403-1406.
4. Penzer R. Emollients: selection and application. *Podiatry Now* 2005; **9**: pS1-S8.
5. Beltraminelli H, Itin P. Skin and psyche - From the surface to the depth of the inner world. *Journal der Deutschen Dermatologischen Gesellschaft* 2007; **6**: 8-14.
6. Lucke T, Munro C, Ronerts D, Springett K & Thomson J. Dermatological conditions of the foot and leg. In Lorimer D, French G, O'Donnell M, Burrows JG (Eds) *Neale's Disorders of the Foot*. London: Churchill Livingstone 2002: 211.
7. O'Donnell M, Lorimer D & Forster M. Clinical therapeutics. In Lorimer D, French G, O'Donnell M, Burrows JG (Eds) *Neale's Disorders of the Foot*. London: Churchill Livingstone 2002: 433.
8. Springett K, Deane M, Dancaster P. Treatment of corns, calluses and heel fissures with a hydrocolloid dressing. *Journal of British Podiatric Medicine* 1997; **52**(7):102-104.
9. Hashimoto H. Superglue for the treatment of heel fissures. *Journal of the American Podiatric Association* 1999; **89**(8): 434-435.
10. Murtha AP, Kaplan AL, Paglia MJ, Mills BB, Feldstein ML, Ruff GL. Evaluation of a novel technique for wound closure using a barbed suture. *Plastic and Reconstructive Surgery* 2006; **117**(6): 1769-1780.
11. Farion KJ, Russell KF, Osmond MH, Hartling L, Klassen TP, Durec T, Vandermeer B. Tissue adhesives for traumatic lacerations in children and adults. *Cochrane Database of Systematic Reviews* 2001; **4**. Art No. CD003326. DOI: 10.1002/14651858.CD003326.
12. Singer AJ, Quinn JV, Hollander JE. The cyanoacrylate topical skin adhesives. *American Journal of Emergency Medicine* 2007; **26**: 490-496.
13. Dockery GL. Mechanical Injuries. In *Cutaneous Disorders of the Lower Extremity*. Pennsylvania: WB Saunders 1997: 242.
14. Saxena AK, Willital GH. Octylcyanoacrylate tissue adhesive in the repair of pediatric extremity lacerations. *Am J Surg* 1999; **65**(5): 470-472.
15. Feldman DL. Which dressing for split-thickness skin graft donor sites? *Annals of Plastic Surgery* 1991; **27**(3): 288-291.
16. Mertz PM, Davis SC, Cazzaniga AL. Barrier and antibacterial properties of 2-octyl cyanoacrylate-derived wound treatment films. *Journal Cutaneous Medicine and Surgery* 2003; **7**: 1-6.

In February 2009, The Society of Chiropodists and Podiatrists issued revised standards for the decontamination of instruments. These recommendations included - separate decontamination areas wherever possible, that automated cleaning methods are utilised such as Ultrasonic cleaners / Washer disinfectors and, most importantly, when purchasing a new autoclave, the model should have a printer attached. By Dec 2010, all autoclaves used in Podiatry should reach 134°C and provide a paper or digital record of all sterilising cycles.

Prestige Medical & ac Medical Ltd



PodiaClave

**ONLY
£995^{vat}**

PodiaClave 9 Ltr

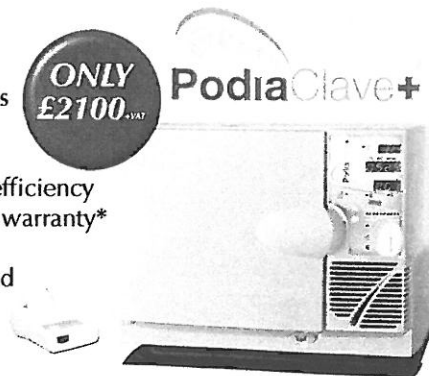- 2010 Compliant
- Printer as standard
- 134°C Cycle

PodiaClave + 16 Ltr

- Vacuum & Non Vacuum cycles
- Printer as standard
- Ideal for pouched instruments
- Large capacity for maximum efficiency
- UK Manufactured with 2 year warranty*
- Full aftercare support
- Fully compliant and CE marked to BS EN13060:2004

**ONLY
£2100^{vat}**

PodiaClave+



* 2 Year warranty subject to annual service carried out by Prestige at 12 months after installation.

For a vast range of products at great prices, call our sales team now.

For sales & support. Contact our team on:

Phone- 01626 777088 • Fax-01626 777253

E mail- info@acmedical.co.uk • web- www.acmedical.co.uk

Post- 28 Brunswick St. Teignmouth, Devon. TQ14 8AF